

Noninvasive transcranial Doppler ultrasound recording of flow velocity in basal cerebral arteries

RUNE AASLID, PH.D., THOMAS-MARC MARKWALDER, M.D., AND HELGE NORNES, M.D.

Department of Neurosurgery, University of Bern, Bern, Switzerland

✓ In this report the authors describe a noninvasive transcranial method of determining the flow velocities in the basal cerebral arteries. Placement of the probe of a range-gated ultrasound Doppler instrument in the temporal area just above the zygomatic arch allowed the velocities in the middle cerebral artery (MCA) to be determined from the Doppler signals. The flow velocities in the proximal anterior (ACA) and posterior (PCA) cerebral arteries were also recorded at steady state and during test compression of the common carotid arteries. An investigation of 50 healthy subjects by this transcranial Doppler method revealed that the velocity in the MCA, ACA, and PCA was 62 ± 12 , 51 ± 12 , and 44 ± 11 cm/sec, respectively. This method is of particular value for the detection of vasospasm following subarachnoid hemorrhage and for evaluating the cerebral circulation in occlusive disease of the carotid and vertebral arteries.

KEY WORDS • arterial flow velocity • collateral flow • ultrasonics • transcranial Doppler ultrasound • cerebral arteries • internal carotid artery • middle cerebral artery

DOPPLER ultrasound recording of the blood flow velocity in the extracranial arteries supplying the brain was reported by Miyazaki and Kato⁶ in 1965 and is now used routinely in neurological and neurosurgical practice.^{1,4} The velocity in the intracranial vessels has been observed by Doppler technique during surgery,^{2,8,9} and in children with open fontanels.⁷ In adults, however, the skull is a severe obstacle to the penetration of ultrasound. Bone strongly attenuates the ultrasonic wave, making it impossible to record noninvasively the blood flow velocity from intracranial arteries by conventional Doppler instruments operating in the range from 5 to 10 MHz. At lower frequencies, 1 to 2 MHz, the attenuation in bone and soft tissues is considerably less. The skull bones are of varying thickness, and because the bone of the temporal region is thin, this would appear to be the most promising area for penetration of ultrasound. In fact, determination of midline deviation, using echo techniques, has demonstrated that some penetration of ultrasound is possible.

The present study investigates the blood flow velocities in the middle, anterior, and posterior cerebral

arteries (MCA, ACA, and PCA) using a noninvasive transcranial Doppler ultrasound technique.

Clinical Material and Methods

Fifty healthy subjects with no history of cerebral vascular disease were investigated. Their ages ranged from 20 to 65 years, with a mean of 36 years.

For the present study we used a laboratory prototype range-gated Doppler instrument with the following characteristics. Emitted ultrasonic frequency 2 mHz; burst repetition rate 6.8 to 18 kHz; burst length 10 μ sec; high pass filter 100 Hz; low pass filter 3.4 to 9 kHz; and emitted ultrasonic power 350 mW. The effective range for this apparatus is from 3.0 to 10 cm. Sampling can be done at preselected distances from the probe within this range by means of a gating system.

The emitting area of the ultrasonic transducer was 1.5 sq cm, which is about 10 times larger than the cross-sectional area of the MCA in adults. Without focusing, only a small portion of the ultrasonic energy can be directed at the location of interest. In addition, the transducer is not effective in receiving the weak Doppler shifted signals from the blood flow. For this

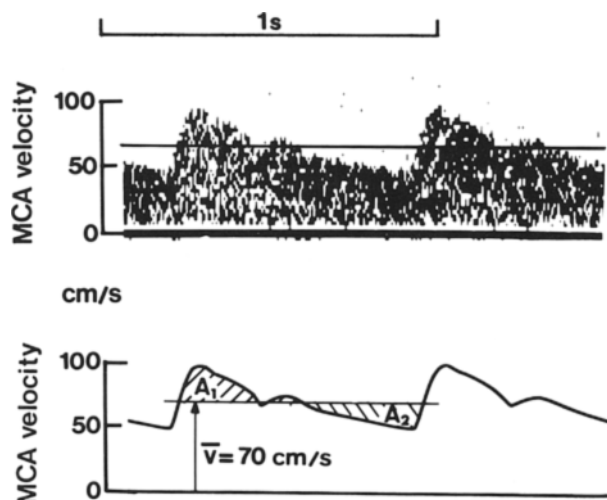


FIG. 1. *Upper:* Spectral display of the Doppler signal from the middle cerebral artery (MCA). The horizontal line through the spectra represents a cursor that can be controlled up or down on the display. *Lower:* The outline of the spectra shown above. The cursor was placed so that the areas A_1 and A_2 were judged equal. The velocity \bar{v} corresponding to this cursor position was calculated using the Doppler equation.

reason, the ultrasonic transducer was equipped with a polystyrene acoustic lens with a focal length of approximately 5 cm. The focused beam had a width of 4 mm at this distance.

The Doppler frequency spectrum was displayed on an Angioscan* frequency analyzer. The Doppler instrument and the frequency-spectrum analyzer have direction discrimination. The normal cognate flow direction of the artery studied was displayed as positive. The end-tidal $p\text{CO}_2$ was determined using an infrared analyzer.

It is difficult to determine the angle between the ultrasonic beam and the direction of the intracranial arteries. However, assuming that the angle is sharp, accurate determinations of the velocity are still possible.^{3,5} If the angle ranges from 0° to 30° , its cosine will vary between 1 and 0.86. Thus, the maximum error will be less than 15%. Under such conditions, one can assume that the true velocity, v (in cm/sec) is given by the relation: $v = 0.039 f$, where f is the Doppler frequency shift (in Hz).

Figure 1 illustrates a spectrum analysis of the Doppler signal from the MCA in a healthy 38-year-old man. The ordinate is expressed in cm/sec, as described above. The time-mean of the outline velocity was determined using the cursor of the spectrum analyzer. The cursor was placed so that the areas A_1 and A_2 were equal. The cursor was also used to determine the systolic and diastolic velocities of the signal.

* Angioscan frequency analyzer manufactured by Uni-gon Industries, Inc., Mount Vernon, New York.

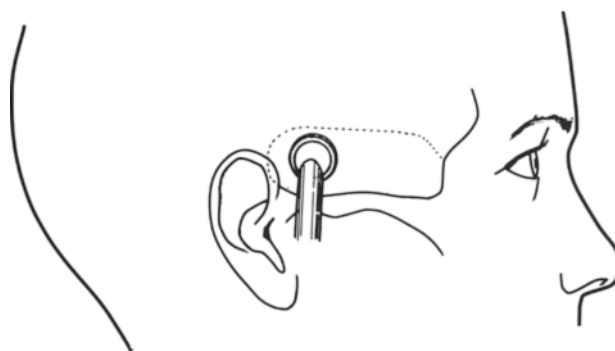


FIG. 2. Diagram of the area (dotted line) where Doppler signals from intracranial arteries were obtained. The zygomatic arch is indicated. The most likely location to obtain signals is shown by the position of the probe.

The exact positioning of the ultrasound probe was rather critical in most subjects. A satisfactory signal could only be obtained in a restricted region above the zygomatic arch, from 1 to 5 cm in front of the ear (Fig. 2). An "ultrasonic window" had to be located in each individual by searching this region to obtain a maximum amplitude of the Doppler signals.

In order to record the velocity in the MCA, we first set the depth of the range-gate to 5.0 cm. Usually the signal was found after a short search (Fig. 3). In difficult cases, probing for several minutes was necessary before obtaining the Doppler signal. Then the depth setting was increased stepwise until the MCA signal became weak. This occurred at a depth of about 6 cm, depending on the skull diameter. By aiming the probe slightly caudally, we obtained signals from the terminal portion of the internal carotid artery (ICA). This artery runs at a blunt angle with the ultrasonic beam. The Doppler signals from the intracranial ICA have lower frequency shifts than those from the MCA.

The probe was then reaimed at the MCA, and the depth of the range-gate was reduced in steps of 0.5 cm. The probe was adjusted for maximum signal at each depth. From 4.5 to 3.5 cm, we could obtain signals from two or more branches. This tracking or scanning procedure could be performed with only slight adjustments in the direction of the probe, indicating that the ultrasonic beam was intercepting the artery at a sharp angle.

The signal from the proximal ACA was obtained by scanning the MCA signal progressively deeper until a velocity in the opposite direction was found. The depth of the range-gate and the tilt of the probe were then adjusted for the best signal from the ACA. The proximal ACA is rather short, and we were not able to track it over a distance of more than 0.5 to 1 cm. The instrument has a finite resolution, and it was sometimes difficult to obtain a proximal ACA signal without interference from the MCA. However, this never caused serious difficulty in interpreting the data,

Doppler recording of cerebral arterial flow

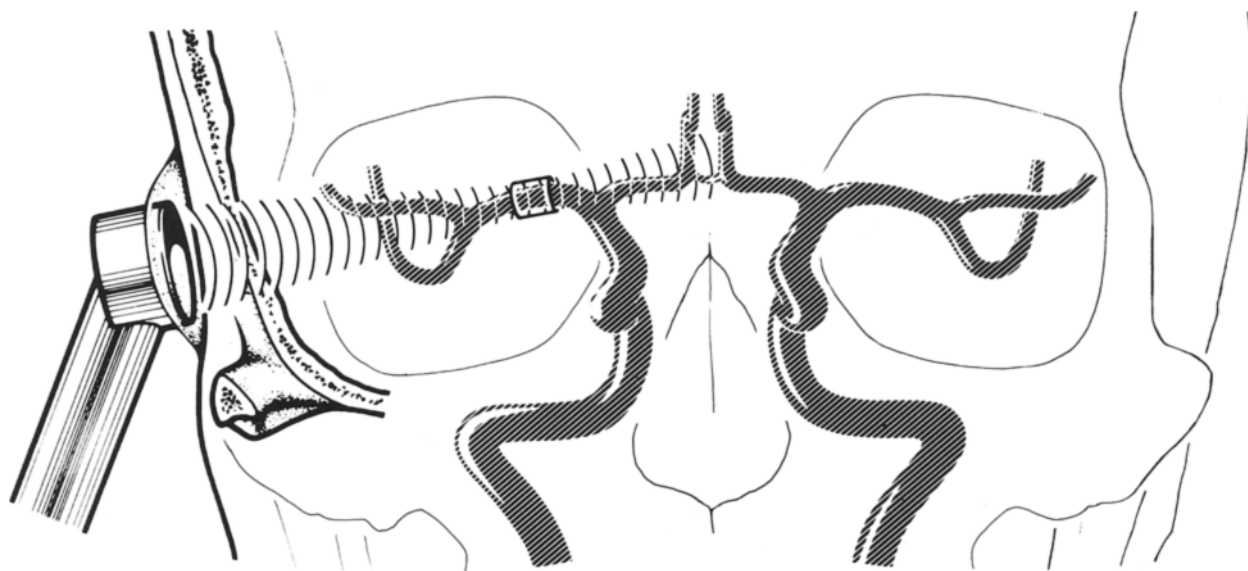


FIG. 3. Frontal view of the ultrasound probe directed toward the middle cerebral artery (MCA). The cylinder around the MCA indicates the observation region (sampling volume) for the Doppler recording. The distance from the middle of the cylinder to the probe corresponds to the depth setting.

as the spectrum analyzer has direction discrimination, allowing velocities in both arteries to be recorded simultaneously.

The PCA signal was obtained by the following procedure. The MCA was located first, then the depth of the range-gate was increased stepwise until the signal became weak and disappeared. Then the probe was tilted and aimed at a location posterior and slightly caudal to that of the MCA signal. This area was searched until we found the Doppler signal. The depth was increased further until the low-frequency Doppler shift from the basilar artery was detected. This was the distal portion of the basilar artery which runs at a blunt angle with the ultrasonic beam. Advancing the depth control still further disclosed flow in the opposite direction. This came from the PCA on the contralateral side. We then tracked the ipsilateral PCA from its origin at the basilar artery and laterally until the Doppler shift was maximal. This depth was used to determine the PCA velocity.

The velocity in the ICA's in the neck was measured using the same Doppler instrument and probe that was used for the transcranial recordings. The probe was placed slightly below the mandibular angle and aimed cranially. The depth of the range-gate was set in the range from 3.5 to 4.0 cm to achieve insonation at a sharp angle (less than 30°). The external carotid artery and the common carotid artery (CCA) were identified so as to ensure that we were recording well above the bifurcation.

Results

Doppler recordings of bilateral MCA blood flow velocities were obtained in all 50 subjects. However,

the Doppler signal was not of sufficient intensity to allow ACA velocity determination in 20% of the arteries investigated. For the PCA this failure rate was 40%.

An MCA velocity recording from a healthy 51-year-old man is shown in Fig. 4 *upper*. The ipsilateral CCA was compressed for approximately 4 seconds, causing an instant drop in the MCA velocity to 60% of control. In this case, the MCA velocity waveform became damped. When the compression was released, the velocity rose to 130% of the control value for a period of 4 to 5 seconds, then returned to the pre-occlusion level (not shown). The probe was then directed slightly caudally until a signal from the terminal ICA was obtained. A new compression test was performed (Fig. 4 *lower*). The velocity fell to zero, and some backflow caused by an external carotid artery "steal" was observed during the systole.

In the same subject, the proximal ACA exhibited a velocity pattern as shown in Fig. 5. The upper panel illustrates a reversal of flow in this artery when the ipsilateral CCA was compressed. The proximal ACA was supplying collateral flow to the MCA on the same side in this situation. During compression, irregular flow or turbulence could be heard in the Doppler signal, particularly in systole. This showed up in the spectra as a brief period of low-frequency noise. We interpret this as the effects of a high-velocity jet from the anterior communicating artery. A recording of the proximal ACA velocity during compression of the contralateral CCA is shown in Fig. 5 *lower*. The velocity increased to 280% of the control value, thus demonstrating an excellent collateral capacity of the anterior circle of Willis.

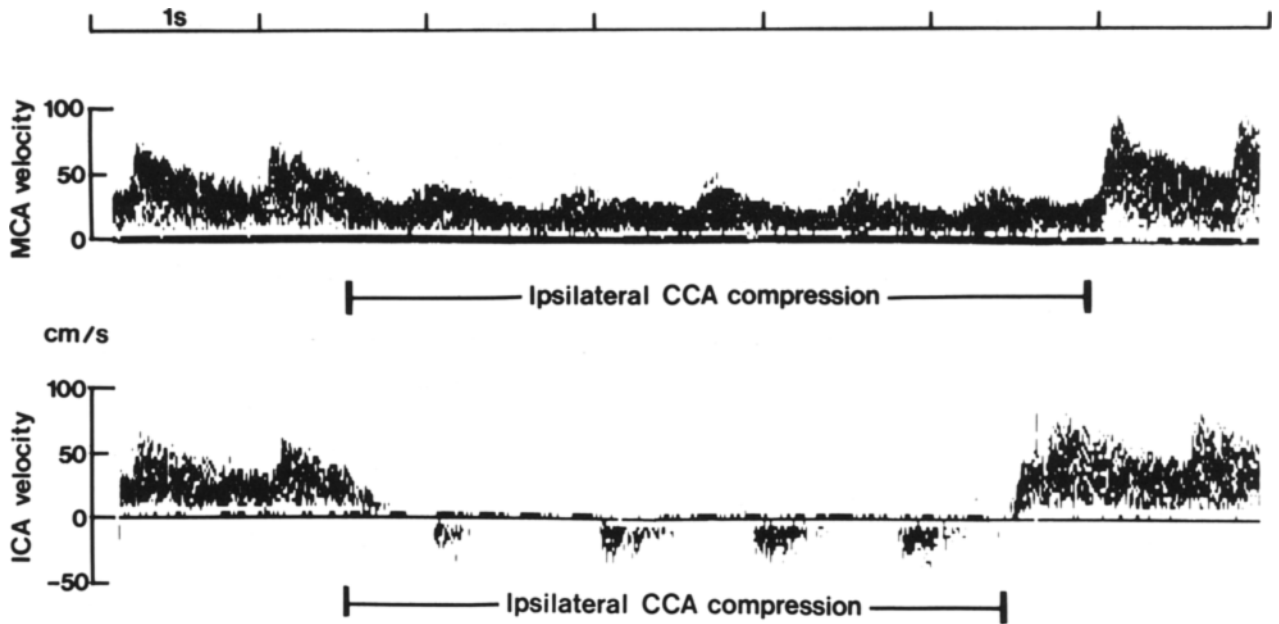


FIG. 4. Spectral display of the Doppler signal from the middle cerebral artery (MCA, *upper*) and the terminal internal carotid artery (ICA, *lower*) during test compressions of the common carotid artery (CCA) on the ipsilateral side in a 51-year-old man. The MCA velocity fell by 40% during compression. Note the reversed systolic flow in the terminal ICA. This indicates external carotid artery "steal."

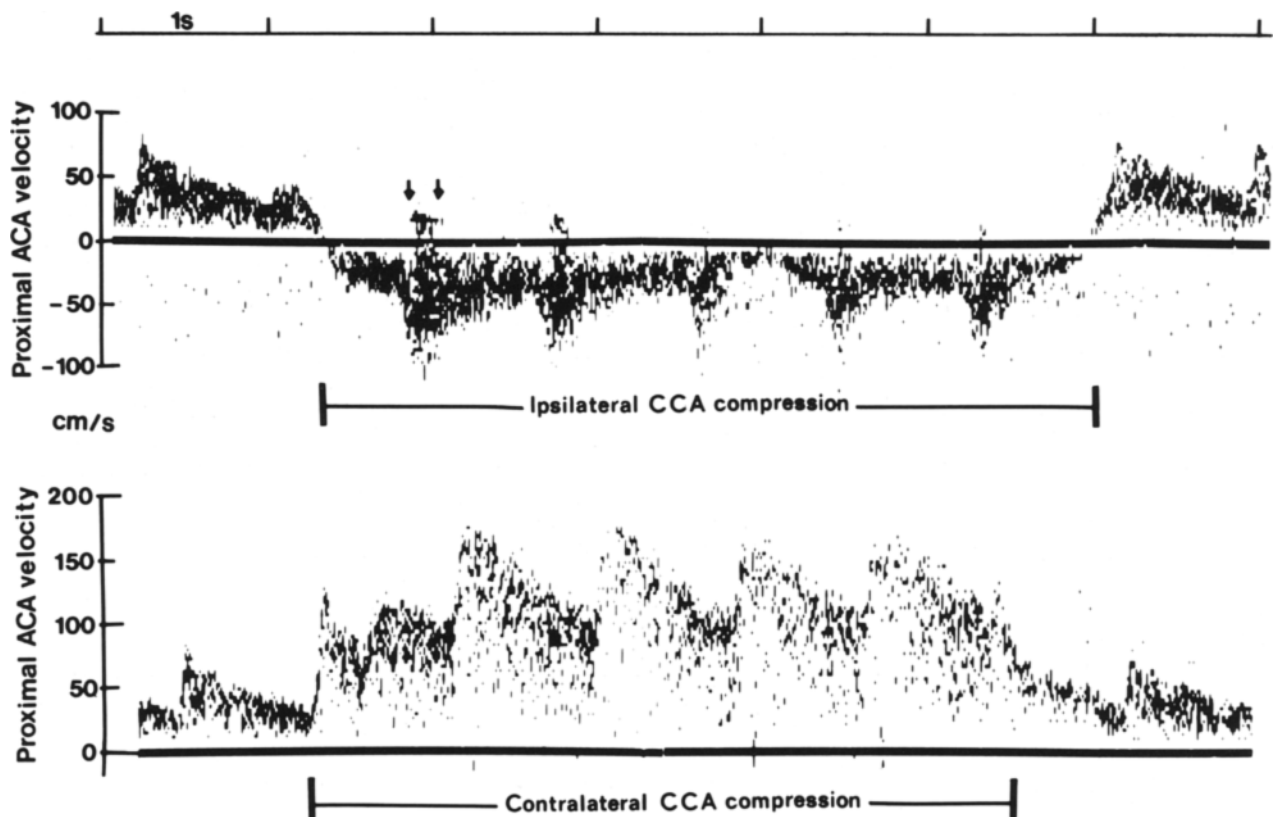


FIG. 5. Spectral display of the Doppler signal from the proximal anterior cerebral artery (ACA) during test compression of the common carotid artery (CCA) on the ipsilateral side (*upper*), and on the contralateral side (*lower*). Arrows indicate irregular flow during systole.

Doppler recording of cerebral arterial flow

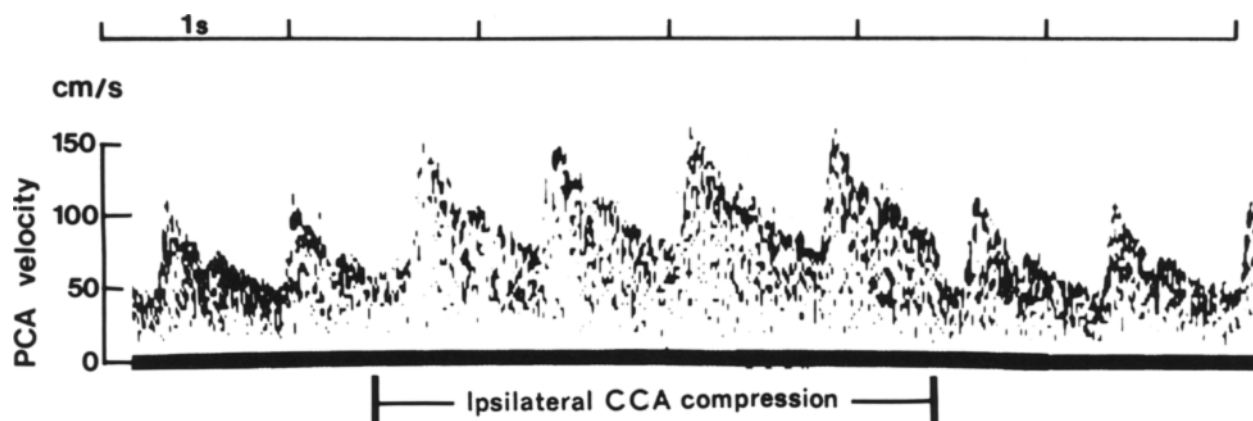


FIG. 6. Spectral display of the Doppler signal from the proximal part of the posterior cerebral artery (PCA) during test compression of the common carotid artery (CCA) on the ipsilateral side. Velocity increased by 60% with return to preocclusion level.

Figure 6 displays a recording of the velocity in the proximal PCA during ipsilateral CCA compression. The velocity instantly rose to 160% of the control value, indicating its potential as a collateral flow source. When the depth of the range-gate was set to a slightly more distal portion of the PCA, we did not record any appreciable change in the velocity during ipsilateral CCA compression. Compression of the contralateral CCA did not influence the ipsilateral PCA velocity (not shown).

The MCA velocities at different depths in 10 subjects are shown in Fig. 7. The lower panel illustrates the mean values of these velocities at the standard depths for MCA recording. Our data show that the MCA velocity was relatively constant over a depth range from 6.0 to 4.0 cm, with slightly more occurring at 5.5 and 5.0 cm.

The MCA velocity in the whole series was 62 ± 12 cm/sec (mean \pm standard deviation), with a range of 33 to 90 cm/sec. The ratio between the MCA velocity on the left side and that on the right side was $1.01 \pm 0.14:1$. Thus, in the normal adult the MCA velocities are nearly equal on the two sides. The MCA velocity did not correlate with age ($r = 0.23$) in this series. The velocity in the ACA was 51 ± 12 cm and that in the PCA was 44 ± 11 cm/sec. The velocities in the extracranial ICA were 37 ± 6.5 cm/sec. The ratio between the velocity in the MCA and that in the extracranial ICA was $1.7 \pm 0.4:1$. The end-tidal pCO_2 was 5.1 ± 0.5 kPa during these studies.

Discussion

A range-gated Doppler instrument with a frequency of 2 MHz has provided satisfactory intracranial recordings of the velocities in the MCA. This artery runs almost directly toward the probe and is thus ideally located for Doppler ultrasonic recording with the technique described.

The ACA and PCA describe comparatively sharp angles with the ultrasonic beam in their proximal parts. The velocities calculated from the spectral display probably reflect values close to true velocities in most individuals. In some subjects, however, the velocities in these arteries may be slightly underestimated and this must be kept in mind when evaluating readings from these two arteries. Our results indicate that the ACA and the PCA will also be within reach in practically all individuals with improvements in the instrumentation, particularly the probe design.

The velocities observed in the present study were in the same range as those found by Doppler techniques during surgery. Also, the responses we obtained to test occlusions of the carotid arteries followed the same pattern as those found in these previous studies.^{8,9} We have never observed higher velocities in the branches of the MCA than in the parent artery, and this concurs with our Doppler findings at operations. The velocities in the ACA and the PCA were generally somewhat lower than in the MCA, but higher than in the extracranial ICA. Thus, our results indicate that in the normal subject the highest velocities in the cerebral circulation are found in the basal cerebral arteries.

The systolic peak velocity in the ACA and the MCA was about 1 m/sec in more than 50% of the individuals in these series. This velocity is of the same magnitude as the systolic velocity in the aorta. It is unusual in the human circulation that arteries only 2 to 4 mm in diameter can exhibit the same peak velocity as in the aorta. Furthermore, it is of particular interest to note that, in humans, aneurysms are most apt to occur in these two arterial areas.

Transcranial Doppler recording gives useful information on the intracranial flow directions and distributions. A special application of the method is the determination of the collateral capacity of the circle

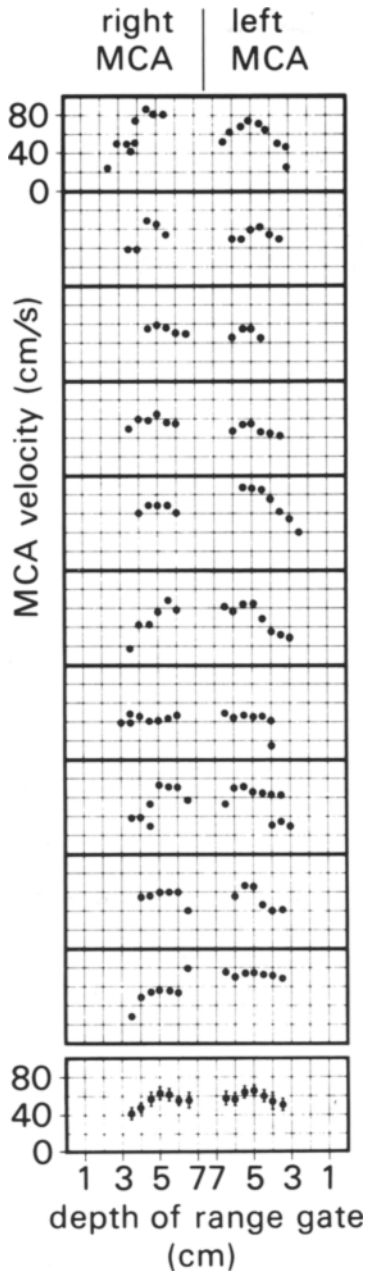


FIG. 7. Diagram of the velocities in the middle cerebral artery (MCA) in 10 normal subjects (10 upper panels). The abscissae are the depth settings at which the velocity determinations were made. Notice that the depths of the left and right sides run toward the midline from each side. If more than one velocity is given at a certain depth, it indicates that determinations in two branches were made. The lower panel represents the means of the MCA velocities in 10 subjects. The standard deviations are indicated by vertical bars.

of Willis. One can assume that the arterial lumen stays relatively constant during CCA test compression. Therefore, the flow velocity in the MCA provides direct information on the relative change in the volume flow when the CCA is occluded. Furthermore, the velocities in the ACA and PCA can be studied in the same way in order to determine their relative contribution to collateral flow.

The transcranial approach can be used for the detection of vasospasms following subarachnoid hemorrhage. When the artery contracts, or the lumen is otherwise reduced, the velocity is practically inversely proportional to the vessel lumen area. Velocities exceeding 200 cm/sec have been observed in spastic arteries (material to be published). Because the method is noninvasive, it can be repeated as often as necessary, and thus be a guide in the timing of operations and in the general handling of these patients.

References

1. Brisman R, Grossman BL, Correll JW: Accuracy of transcutaneous Doppler ultrasonics in evaluating extracranial vascular disease. *J Neurosurg* 32:529-533, 1970
2. Friedrich H, Hänsel-Friedrich G, Seeger W: [Intraoperative Doppler sonography of brain vessels.] *Neurochirurgia (Stuttg)* 23:89-98, 1980 (Ger)
3. Holen J, Aaslid R, Landmark K, et al: Determination of pressure gradient in mitral stenosis with a non-invasive ultrasound Doppler technique. *Acta Med Scand* 199:455-460, 1976
4. Keller H: Die cerebrovasculäre Doppler-Ultraschall-Untersuchung (cv-Doppler). *Bull Schweiz Akad Med Wiss* 36:129-142, 1980
5. Light H: Transcutaneous aortovelocity. A new window on the circulation? *Br Heart J* 38:433-442, 1976
6. Miyazaki M, Kato K: Measurement of cerebral blood flow by ultrasonic Doppler technique. *Jpn Circ J* 29:375-382, 1965
7. Muchaidze YA, Syutkina EV: Determination of the linear velocity of the cerebral blood flow in premature infants. *Hum Physiol* 5:595-599, 1979
8. Nornes H, Grip A, Wikeby P: Intraoperative evaluation of cerebral hemodynamics using directional Doppler technique. Part 1: Arteriovenous malformations. *J Neurosurg* 50:145-151, 1979
9. Nornes H, Grip A, Wikeby P: Intraoperative evaluation of cerebral hemodynamics using directional Doppler technique. Part 2: Saccular aneurysms. *J Neurosurg* 50:570-577, 1979

Manuscript received May 13, 1982.

Address reprint requests to: Rune Aaslid, Ph.D., Neurochirurgische Klinik, Inselspital, CH-3010 Bern, Switzerland.